

Pseudoaneurysm of common carotid due to trauma: treatment option for open sky surgery

Pseudoaneurisma de carótida comum secundário a trauma contuso: opção de tratamento por cirurgia a céu aberto

Edson Pedroza dos Santos Junior¹, Rodolfo Rogers Américo Machado Batista¹, Maykon Brescancin de Oliveira², Remy Faria Alves², Ricardo Russi Blois²

Abstract

Case report of a female patient, 44 years-old, victim of cervical trauma in a traffic accident, who had painful cervical mass, associated with hoarseness and dysphagia three weeks after trauma. Additional tests identified the pseudoaneurysm of common carotid artery in zone II. We opted for treatment through the open conventional surgery with excellent immediate result. Control examination was performed seven months after surgery, and the results confirmed the therapeutic success.

Keywords: pseudoaneurysm; extracranial carotid; surgery.

Resumo

Relato de caso de paciente feminina, com 44 anos de idade, vítima de trauma cervical em acidente de trânsito, que apresentou massa cervical dolorosa, rouquidão e disfagia associados, três semanas após o trauma. Exames complementares identificaram pseudoaneurisma de carótida comum em zona II. Optou-se pelo tratamento por meio de cirurgia convencional a céu aberto com excelente resultado imediato. Foi realizado um exame de controle após sete meses do procedimento cirúrgico, e os resultados confirmaram o sucesso terapêutico.

Palavras-chave: pseudoaneurisma; carótida extracraniana; cirurgia.

Introduction

Cervicothoracic vascular trauma represents a challenge for surgeons, irrespective of the latest advances in diagnostic and surgical techniques. Lesions from penetrating or blunt vascular trauma have low prevalence, but morbidity and mortality rates remain high¹.

Carotid artery rupture caused by blunt trauma accounts for 3 to 10% of all carotid lesions². The incidence of carotid artery lesions due to blunt trauma has been reported to vary from 0.08 to 0.33%, and up to half the patients do not present signs of cervical trauma or neurologic deficit. The known mechanism of lesions are: cervical hyperextension-rotation (most common);

direct trauma to the neck; intraoral trauma and basilar skull fracture¹.

Cervical trauma is the leading cause of carotid artery pseudoaneurysms (PA)³. The mechanism of injury is rupture of the arterial wall, leading to local hemorrhage that is contained by adjacent structures, forming a pulsatile hematoma, or pseudoaneurysmal sac. Clinically, they present as: a pulsatile mass on the neck, symptoms of compression of adjacent structures, bleeding or neurologic deficits^{1,2}.

Traditionally, the treatment of choice is open surgical repair³. Nevertheless, endovascular techniques, such as stenting, endografting, and balloon angioplasty have been increasingly used to repair the carotid lesions, making it possible to treat those lesions with a lesser risk of complications^{3,4}.

Study carried out at the Service of Vascular and Haemodynamic Surgery Hospital e Maternidade Dom Orione – Araguaína (TO), Brazil.

¹Physicians of Instituto Tocantinense Presidente Antonio Carlos – Araguaína (TO), Brazil.

²Physician; Vascular surgeon; Professor of Clinical Surgery at Instituto Tocantinense Presidente Antonio Carlos – Araguaína (TO), Brazil.

Conflict of interests: nothing to declare.

Submitted on: 03.25.11. Accepted on: 06.27.11.

J Vasc Bras. 2011;10(3):261-265.

Case report

A 44 year-old female patient, victim of motorcycle accident, was admitted with blunt craniocervical trauma, without loss of consciousness or neurologic deficit. Three weeks after conservative treatment for her cranioencephalic trauma, she was seen in the Outpatient Clinic. She was classified as 15 in the Glasgow scale, had no impairment of cranial nerves and complained of a painful tumor in the left lateral aspect of the neck, with hoarseness and dysphagia. Doppler ultrasonography showed a pseudoaneurysm with turbulent flow outside the left common carotid artery, medially and below the carotid bulb (Figure 1 to 2). Digital angiography was

then performed to confirm the diagnosis, for surgical planning, and to exclude associated lesions. It confirmed a carotid pseudoaneurysm, with lateral displacement of the distal common carotid artery (Figure 3).

The decision was made to perform open repair of the pseudoaneurysm, under general anesthesia. An oblique 8-cm-long incision was made along the anterior border of the sternocleidomastoid muscle. The common carotid artery and its branches were dissected (Figure 4) and the patient was given systemic heparin (5,000 UI IV). The common, internal and external carotid arteries were clamped, the pseudoaneurysm opened and its contents evacuated. A small laceration of the arterial wall was found and sutured, and the arterial blood flow was reestablished.

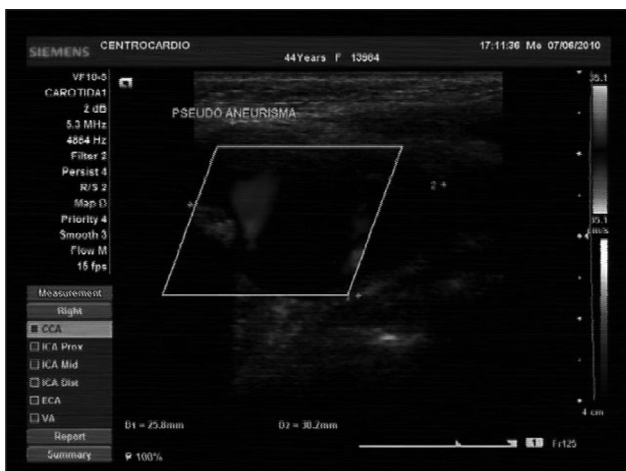


Figure 1. Collection at the distal portion of the common carotid artery measuring 25 x 30 mm with flow, and artery lateralization.

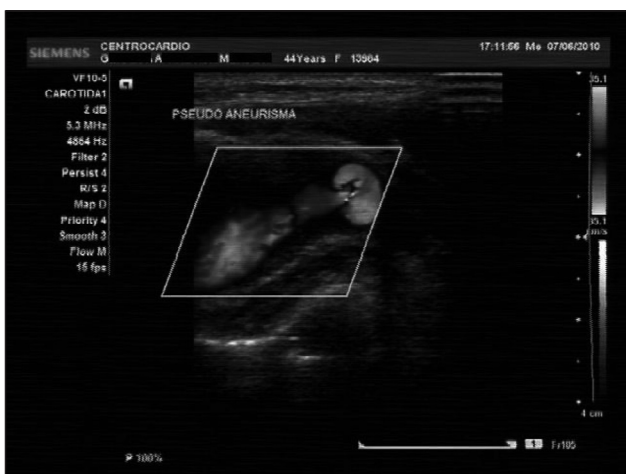

Figure 2. Communication of the carotid flow with the aneurysmal sac.

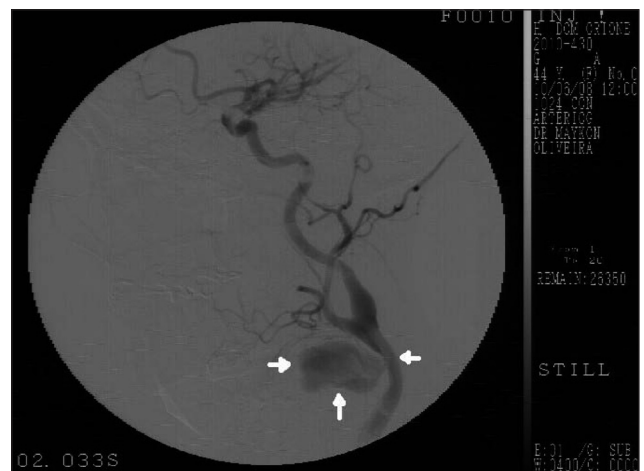


Figure 3. Carotid pseudoaneurysm and arterial lateralization.

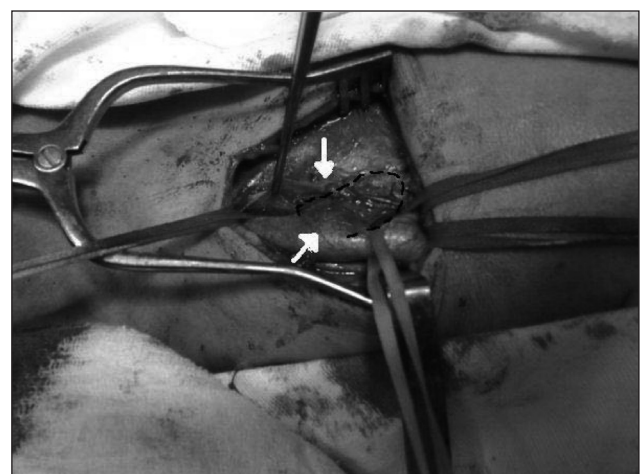


Figure 4. Intraoperative arterial control and identification of the aneurysmal sac.

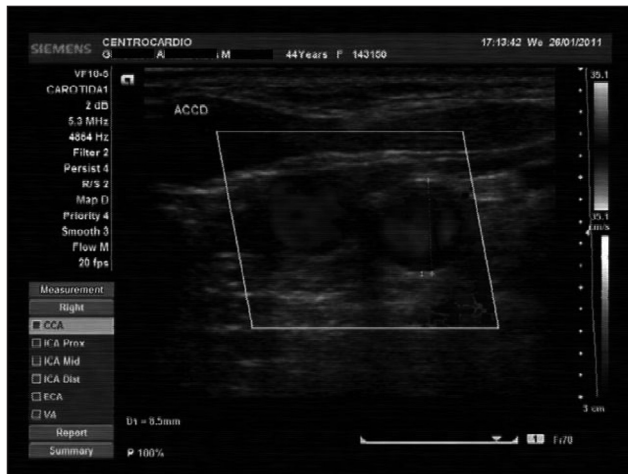

Figure 5. Follow-up Doppler ultrasonography seven months after procedure.

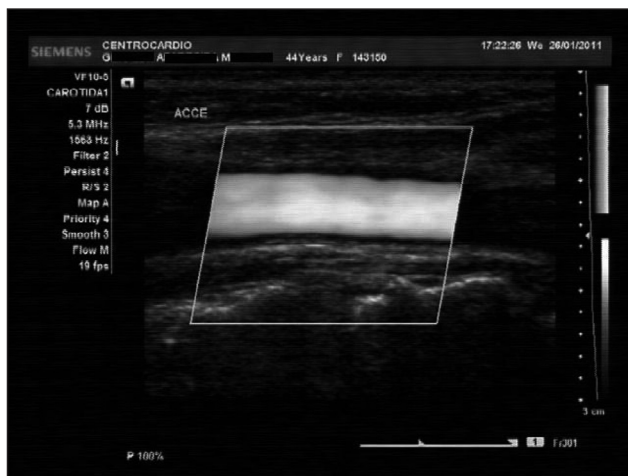


Figure 6. Doppler ultrasonography: common carotid artery near the bulb without lesions seven months later.

The patient was discharged from hospital on the third postoperative day in good condition, with no neurologic deficits or signs of local bleeding. An antiplatelet agent was prescribed. The patient was seen at the outpatient clinics 15 days after the operation and presented no complications. At the follow-up visit seven months after the operation, Doppler ultrasonography was normal (Figures 5 to 6) and clinical examination did not show any sequelae.

Discussion

Patients with extracranial carotid pseudoaneurysms present variable clinical pictures: from a palpable and

pulsatile cervical mass to strokes with definitive neurological deficits⁵. Ischemic symptoms are caused by impaired carotid artery flow or by distal embolism³. Dysphagia and respiratory distress can also be observed^{1,5}, as in the case reported.

The diagnosis of carotid pseudoaneurysm is important because of the drastic consequences of its rupture or distal embolization. There is also the possibility of mistaking its clinical picture for a tonsillar abscess or arteriovenous fistula, whose managements are quite different. The differential diagnosis must include carotid body tumors, tortuosity and kinking of the subclavian and carotid arteries, lymphadenomegaly or arterial tumors⁶.

The imaging exam of choice for diagnosis of carotid pseudoaneurysm is digital arteriography, that is recommended when the clinical presentation or Doppler ultrasonography suggest this entity. CT angiography has been described as a good choice for the diagnosis of pseudoaneurysm, with sensitivity of 100% and specificity of 90%. It is a fast, non-invasive, and low-cost method that has high-spatial-resolution and is not operator-dependent. It can be performed in critically ill patients, such as those with multiple trauma with vascular involvement^{5,7}.

Conventional angiography is the classic method for diagnosis of pseudoaneurysms⁸. However, some authors question this statement, and state that conventional angiography may fail and is not indispensable, for it is invasive and has the limitation of not evaluating bones and adjacent tissues⁷.

Historically, the treatment of pseudoaneurysm has been quite discussed. Some studies have described open repair as the treatment of choice for traumatic carotid pseudoaneurysms, especially extracranial ones, because they present low rates of spontaneous resolution, when treated medically^{7,9}. Extracranial pseudoaneurysms, when are small, inaccessible or located distally to the origins of brain vessels, may be treated with anticoagulation and medical follow-up. Surgical procedures recommended for arterial pseudoaneurysms include arterial wall repair using venous patch in most cases, and also end-to-side anastomosis, tangential repair, endovascular stenting and extra-anatomic bypass¹⁰.

Less invasive endovascular procedures, such as balloon occlusion and placement of covered stents, are believed to be the therapeutic methods of the future. Such techniques have been used to treat traumatic pseudoaneurysms and allowing preservation of the common carotid artery, with the advantage of a shorter operative

time, compared to conventional open repair^{1,3,6,11}. Stenting excludes the pseudoaneurysm permanently from the circulation. However, this technique is not free of complications: it may cause thrombosis and low local blood flow which favors platelet aggregation and microembolic events, stenosis^{1,9,12} and some other problems, such as the need for anticoagulation for life, stent deformities and kinking, and neointimal hyperplasia⁶.

The conventional surgical treatment of penetrating arterial lesions at the base of the skull remains the standard approach. This technique, however, is extremely challenging¹³. Sencer et al. reported cases of patients with internal carotid pseudoaneurysm, associated with carotid-cavernous fistula, who presented with massive epistaxis and ophthalmic signs and symptoms. Endovascular embolization was successful¹⁴. Transarterial embolization with detachable balloons has been accepted as treatment of choice for carotid-cavernous fistula. This technique, however, results in a pseudoaneurysm formation rate of 30 to 40%¹⁵. New generations of stents could make endovascular therapy the treatment of choice for such difficult lesions in the long-term^{16,17}.

Injury or compression of adjacent structures, as seen in the present case, plus the location near the carotid bifurcation, led us to choose open surgical repair. Placement of a stent at the orifice of the pseudoaneurysm, which was close to origin of the internal carotid artery, could have caused impairment of cerebral blood flow. Preservation of carotid perfusion was the desirable goal in this case.

Conclusion

Trauma to the neck may result in blood vessel injury and rarely, to arterial pseudoaneurysm formation. However, this event must be promptly diagnosed and treated due to its high risk of morbidity and mortality.

The dearth of clinical studies in the literature comparing conventional and endovascular treatment of pseudoaneurysms make it difficult to compare those two methods.

In the case reported, the choice of conventional open repair was based on the pseudoaneurysm features, and a good immediate result was achieved, as normal flow in the vessel was shown at Doppler ultrasonography. As the patient presented no neurologic deficits, the choice of treatment was considered adequate.

References

1. Rutherford. *Cirurgia Vascular. Lesões das Artérias Carótidas e Vertebrais*. Cap. 70. Rio de Janeiro: Dilivros; 2007. p.1006-16. 6ed.
2. Sá PM, Machado MC, Silva DA, Brito LL, El Hassan S. Epistaxe tardia secundária a pseudoaneurisma intracavernoso de carótida interna. *Rev Bras Otorrinolaringol*. 2003;69(5):715-8.
3. Oliveira AF, Kajita D, Garzon RGA, Centola APC, Bosnardo CAP, Neto MF. Tratamento endovascular de pseudo-aneurisma de carótida interna em criança. *J Vasc Br*. 2006;5(1):67-70.
4. Zanini MA, Tahara A, dos Santos GS, de Freitas CCM, Jory M, Caldas JGMP, et al. Pseudoaneurysm of the Internal Carotid Artery Presenting with Massive (recurrent) Epistaxes. *Arq Neuropsiquiatr*. 2008;66(2-A):268-71.
5. Väärämäki S, Piminenoff G, Heikkinen M, Suominen V, Saarinen J, Zeitlin R, et al. Ten-year outcomes after endovascular aneurysm repair (EVAR) and magnitude of additional procedures. *Scand J Surg*. 2007;96(3):221-8.
6. Bredt CFG, França LHG, Back LA, Machado EL, Jacobovicz C, Júnior HJS. Aneurisma Gigante de Carótida Interna: Tratamento Cirúrgico. *Hospital de Clínicas da UFPR. J Vasc Surg*. 2003.
7. Romanus AB, Mazer S, Carvalho AN, Liu CB, De Toni FS, Jacob GVV, et al. Pseudo-aneurismas – relato de dois casos e revisão da literatura. *Radiol Bras*. 2002;35(5):303-6.
8. Bush RL, Lin PH, Dodson TF, Dion JE, Lumsden AB. Endoluminal stent placement and coil embolization for the management of carotid artery pseudoaneurysms. *J Endovasc Ther*. 2001;8:53-61.
9. Kasthoori JJ, Nawawi O. Endoluminal Stent Placement in the Management of Recurrent Carotid Blowout Syndrome. *J HK Coll Radiol*. 2007;10:62-5.
10. Coldwell DM, Novak Z, Ryu RK, Brega KE, Biffi WL, Offner PJ, et al. Treatment of posttraumatic internal carotid arterial pseudoaneurysms with endovascular stents. *J Trauma*. 2000;48:470-2.
11. Yi AC, Palmer E, Luh GY, Jacobson JP, Smith DC. Endovascular treatment of Carotid and Vertebral Pseudoaneurysms with Covered Stents. *Am J Neuroradiol*. 2008;29:983-7.
12. Zhang YS, Yang XJ, Wang SZ, Qiao AK, Chen JL, Zhang KY, et al. Hemodynamic effects of stenting on wide-necked intracranial aneurysms. *Chin Med J (Engl)*. 2010;123(15):1999-2003.
13. Garcia MRT, Chammas MC, Caiado AHM, Juliano AG, Leite CC, Cerri GG. Aneurisma da artéria carótida interna extracraniana: Relato de caso. *Radiol Bras*. 2004;37(4):295-7.
14. Sencer S, Minareci O, Poyanli A. Posttraumatic Damage To The Internal Carotid Artery. Pseudo aneurysm Presenting With Epistaxis And Direct Carotid Cavernous Fistula. *Turkish Neurosurg*. 2002;12:128-34.
15. Fang C, Li MH, Tan HQ, Zhang PL, Zhou B. Endovascular treatment of pseudo-aneurysm occurring after embolization of traumatic carotid cavernous fistula with detachable balloons. *Chin Med J (Engl)*. 2008;121(15):1487-91.

16. Mcneil CJD, Chiou MAC, Gunlock MMG, Grayson CDE, Soares MG, Hagino MRT. Successful endovascular therapy of a penetrating zone III internal carotid injury. *J Vasc Surg.* 2002;36:187-90.
17. Baum AR, Stavropoulos SW, Fairman RM, Carpenter JP. Endoleaks after Endovascular Repair of Abdominal Aortic Aneurysms. *JVasc Interv Radiol.* 2003;14:1111-7..

Correspondence

Edson Pedroza dos Santos Junior
Rua Alfredo Nascier, 828, Centro
CEP 77600-000 – Paraíso do Tocantins (TO), Brasil

Author's contribution

Conception and design: MBO
Analysis and interpretation: EPSJ, RRAMB, MBO, RFA
Data collection: EPSJ, RRAMB
Writing the article: EPSJ, RRAMB
Critical revision of the article: MBO, RFA, RRB
Final approval of the article*: EPSJ, RRAMB, MBO, RFA, RRB
Statistical analysis: EPSJ, RRAMB, MBO
Overall responsibility: MBO, RFA, RRB

*All authors have read and approved of the final version of the article submitted to J Vasc Bras.