

## True isolated deep femoral artery aneurysm associated with peripheral artery disease: case report

### *Aneurisma verdadeiro isolado de artéria femoral profunda associado a doença arterial periférica: relato de caso*

Vinicius Tadeu Ramos da Silva Grillo<sup>1</sup> , Rodrigo Gibin Jaldin<sup>1</sup> , Nathália Dias Sertório<sup>1</sup>, Matheus Bertanha<sup>1</sup> , Marcone Lima Sobreira<sup>1</sup> , Ricardo de Alvarenga Yoshida<sup>1</sup> , Winston Bonetti Yoshida<sup>1</sup>

#### Abstract

True deep femoral artery aneurysms are extremely rare, accounting for about 0.5% of all peripheral aneurysms. In this report, we describe a 79-year-old male patient with a history of prior abdominal aortic aneurysm surgery via a conventional approach who was admitted to the vascular surgery service at the Hospital das Clínicas with intermittent claudication of the lower limbs. Arterial color-Doppler ultrasonography of the right lower limb was performed, revealing peripheral arterial disease of the femoral–popliteal and infrapatellar segments. Computed tomography angiography identified aortoiliac and bifurcated graft occlusion from the infrarenal segment of the aorta, in addition to a deep femoral artery aneurysm with diameters of 3.7 cm x 3.5 cm and length of 7 cm. Resection of the aneurysm was followed by revascularization of the deep femoral artery by interposition of a Dacron<sup>®</sup> graft and reimplantation of the superficial femoral artery into the graft. In cases of deep femoral artery aneurysms with concomitant peripheral arterial disease, it is important to ensure revascularization and adequate perfusion of the lower limb.

**Keywords:** femoral artery; aneurysm; peripheral arterial disease; vascular surgical procedures.

#### Resumo

Os aneurismas verdadeiros de artéria femoral profunda são extremamente raros, representando cerca de 0,5% do total dos aneurismas periféricos. Neste relato, descrevemos um paciente de 79 anos de idade, sexo masculino, com histórico de abordagem cirúrgica prévia convencional devido a aneurisma de aorta abdominal, que deu entrada no Serviço de Cirurgia Vascular do Hospital das Clínicas com quadro de claudicação intermitente de membros inferiores. Foi realizado eco-Doppler colorido arterial do membro inferior direito, que revelou doença arterial periférica femoro-poplíteia e infrapatelar. A angiotomografia computadorizada identificou oclusão aortoiliaca e do enxerto bifurcado desde o segmento infrarenal da aorta, além de aneurisma de artéria femoral profunda de 3,7 x 3,5 cm de diâmetro com 7 cm de extensão. Procedeu-se com a ressecção do aneurisma e revascularização da artéria femoral profunda por interposição de prótese de Dacron<sup>®</sup> e reimplante de artéria femoral superficial na prótese. Portanto, nos casos de aneurisma de artéria femoral profunda concomitante a doença arterial periférica, deve-se atentar para revascularização e perfusão adequada do membro inferior.

**Palavras-chave:** artéria femoral; aneurisma; doença arterial periférica; procedimentos cirúrgicos vasculares.

**How to cite:** Grillo VTRS, Jaldin RG, Sertório ND, et al. True isolated deep femoral artery aneurysm associated with peripheral artery disease: case report. J Vasc Bras. 2021;20:e20200220. <https://doi.org/10.1590/1677-5449.200220>

<sup>1</sup> Universidade Estadual Paulista “Júlio de Mesquita Filho” – UNESP, Hospital das Clínicas da Faculdade de Medicina de Botucatu – HC-FMB, Serviço de Cirurgia Vascular e Endovascular, Botucatu, SP, Brasil.

Financial support: None.

Conflicts of interest: No conflicts of interest declared concerning the publication of this article.

Submitted: November 24, 2020. Accepted: January 07, 2021.

The study was carried out at Hospital das Clínicas, Faculdade de Medicina de Botucatu, Universidade Estadual “Júlio de Mesquita Filho” (UNESP), Botucatu, SP, Brazil.



Copyright© 2021 The authors. This is an Open Access article distributed under the terms of the Creative Commons Attribution License, which permits unrestricted use, distribution, and reproduction in any medium, provided the original work is properly cited.

## INTRODUCTION

Aneurysms of the deep femoral artery (DFA) are defined as those that do not continue to an aneurysm of the common femoral artery (CFA). True DFA aneurysms are extremely rare, accounting for around 0.5% of all peripheral aneurysms and 1-2.6% of femoral aneurysms.<sup>1-5</sup> In the majority of cases, etiology is atherosclerotic and they are more common in men (92%) with a mean age of approximately 70 years.<sup>6-8</sup>

There are no precise criteria in the current literature for defining surgical indications or the best treatment techniques for aneurysms of the DFA, which is a result of their rarity and the scarcity of studies of their natural history.<sup>4,5,7,9</sup> In this study, we describe an option for surgical treatment in a patient with an isolated DFA aneurysm with concomitant peripheral arterial disease (PAD). The Research Ethics Committee approved this study (decision number 4.699.360).

## CASE REPORT

The patient was a 79-year-old white male with Japanese ancestry who was seen at the vascular surgery service of the Hospital das Clínicas complaining of pain in the right hip and lower limb intermittent claudication limiting him to 100 meters, with no pain at rest or trophic lesions, but which had worsened over the previous 4 months, increasing in intensity. He had a history of systemic arterial hypertension, was an ex-smoker (five pack-years), having quit more than 50 years previously, and had been treated with aortoiliac interposition of a bifurcated Dacron® graft to repair an infrarenal aortic aneurysm at a different service 16 years before. The graft had become occluded 5 years before the current presentation.

On physical examination, he was in good general health, with an abdominal scar from the previous laparotomy. A pulsating bulge with fibroelastic consistency was palpable in the right inguinal region. Femoral pulses were weak bilaterally (2+/4+) and popliteal and distal pulses were absent. Ankle-brachial indices (ABI) were calculated bilaterally. On the right, Doppler ultrasound did not detect flow in the anterior tibial artery and the posterior tibial and fibular arteries had ABIs of 0.42 and 0.21 respectively. On the left, ABIs for the anterior tibial, posterior tibial, and fibular arteries were 0.47, 0.63, and 0.42, respectively. There were no trophic ulcers.

A supplementary examination was performed using color Doppler ultrasonography (CDU) of the arteries of the right lower limb, revealing stenosis and segmental subocclusion of infrapatellar arteries. The patient was sent for computed tomography angiography

(CTA) of the abdomen and pelvis, which identified aortoiliac occlusion (within the Dacron® graft) starting in the infrarenal segment of the aorta. The CFAs were patent because of refilling via large caliber collateral circulation originating in the inferior epigastric arteries and the internal thoracic arteries. Additionally, a DFA aneurysm was found with diameters of 3.7 and 3.5 cm (anteroposterior and lateral, respectively), length of 7 cm (Figure 1), and intraluminal thrombi. Image reconstruction was employed to enable analysis of the aneurysm's anatomic relationships (Figure 2).

Since surgery was needed, a preoperative risk assessment was performed, classifying the patient as at moderate risk of cardiovascular complications.<sup>10</sup> Since technical and tactical difficulties were expected,

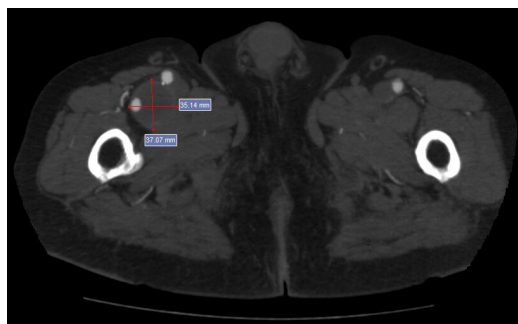


Figure 1. Axial image from computed tomography angiography (CTA) of the proximal thigh, showing an aneurysmal dilatation of the deep femoral artery (DFA) with diameters of 3.7 cm (anteroposterior) and 3.5 cm (lateral) and intraluminal thrombi.

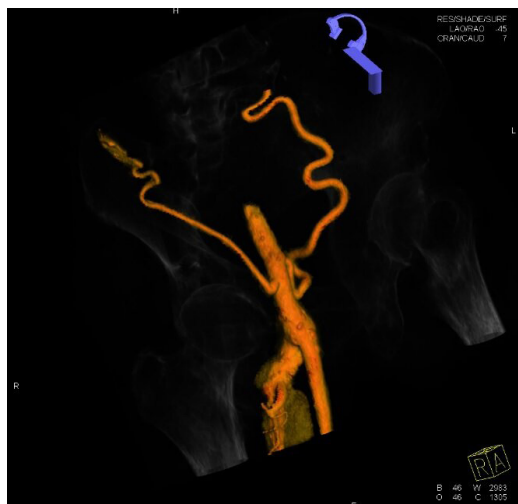


Figure 2. Three-dimensional reconstruction of computed tomography angiography (CTA) with bony landmarks, showing refilling of the common femoral artery (CFA) by collaterals and the aneurysmal dilatation of the deep femoral artery (DFA), with no involvement of the CFA or of the superficial femoral artery (SFA).

endovascular techniques were ruled out because of the postoperative history of aortoiliac revascularization with occlusion of the graft and lower limb PAD.

Surgical access was achieved via a large vertical groin incision, slightly lateral of the conventional approach. The CFA and superficial femoral artery (SFA) were identified and isolated, both of which were ectatic, followed by the DFA, which exhibited an aneurysm starting distal of its origin at the bifurcation and following a posterior-inferior course for approximately 7 cm before the caliber returned to normal (Figure 3). Resection of the aneurysm and revascularization of the DFA were performed. Techniques such as embolization or ligation were ruled out because of the coexisting diffuse atheromatosis of the SFA and occluded arteries of the leg, since the DFA was considered an important source of collateral circulation to perfuse the limb. After safely isolating the proximal and distal arterial segments and positioning the DeBakey atraumatic clamps, the aneurysmal segment was resected. The DFA was revascularized first, to reduce the duration of limb ischemia, since the coexisting PAD meant that the DFA was responsible for distal perfusion. Next, an 8 mm Dacron® graft was interposed end-to-end from the CFA to the healthy distal neck of the DFA and then the SFA was sectioned and reimplanted into the prosthesis, ensuring the path with the best anatomic fit (Figure 4). At the end of the procedure, pulses were palpable before and after the anastomoses with no asymmetry or thrill. Since the patient was neither claudicant nor ischemic, the decision was taken not to perform conventional or endovascular distal revascularization, since to do so could have increased the morbidity and mortality of the procedure. A vacuum drain was fitted into the subcutaneous tissue because of the large dead-space caused by the size of the aneurysm. The surgical specimen (Figure 5) was sent for pathological analysis, which detected probable atherosclerotic origin, with calcified plaque and fibrin-hematic thrombus in the lumen (Figures 6 and 7). The patient progressed well, the drain was removed on the second postoperative day (POD), and he was discharged from hospital on the fifth POD. At 14 and 30-day outpatient follow-ups, the surgical wound was fully healed over and the patient had no complaints of pain or vascular or neurological disorders. Physical examination found that the palpable femoral pulses were maintained bilaterally (2+/4+) and popliteal and distal pulses were still absent. The extremity of his right lower limb was warm and his capillary refill time was less than 3 seconds.

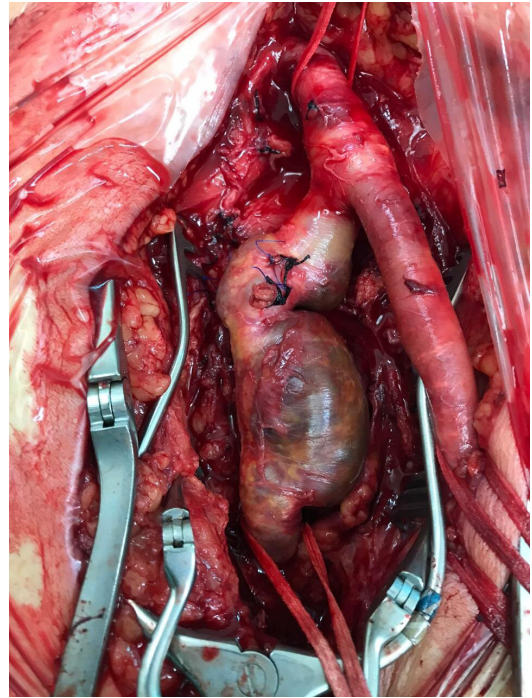


Figure 3. Result of surgical dissection, after proximal repair of the common femoral artery (CFA) and distal repair of the superficial femoral artery (SFA) and deep femoral artery (DFA) beyond the dilation. Note the ligation of branches from the DFA aneurysm.

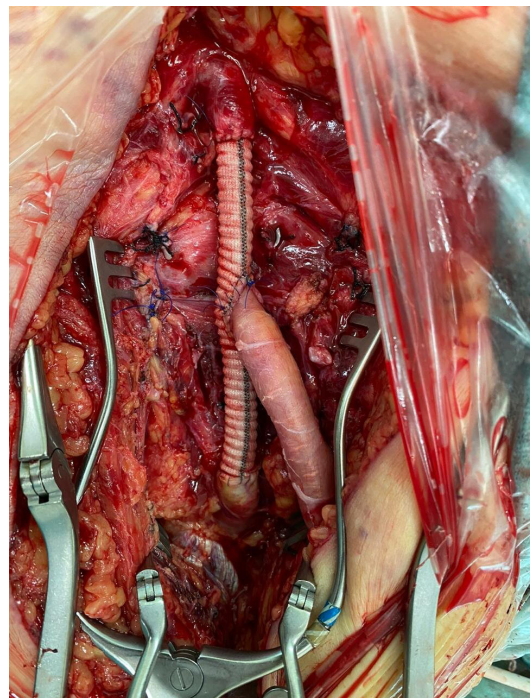
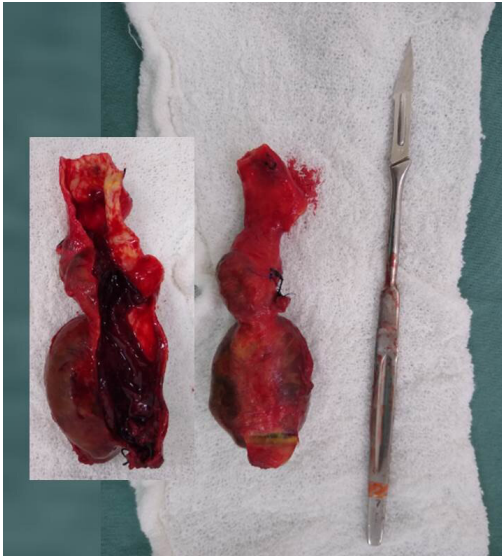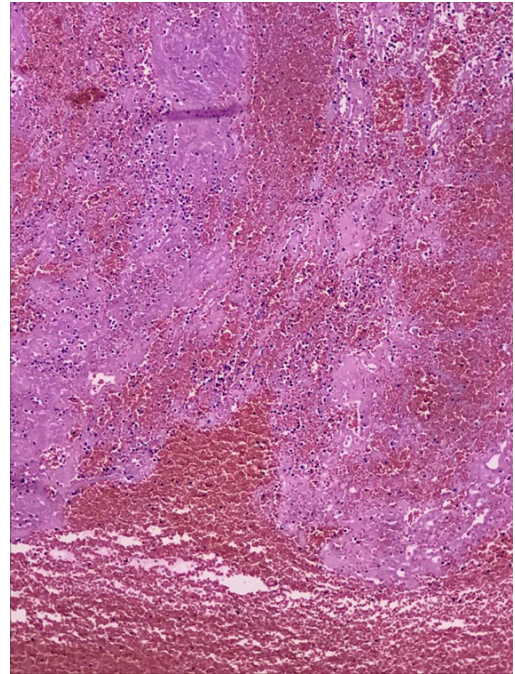


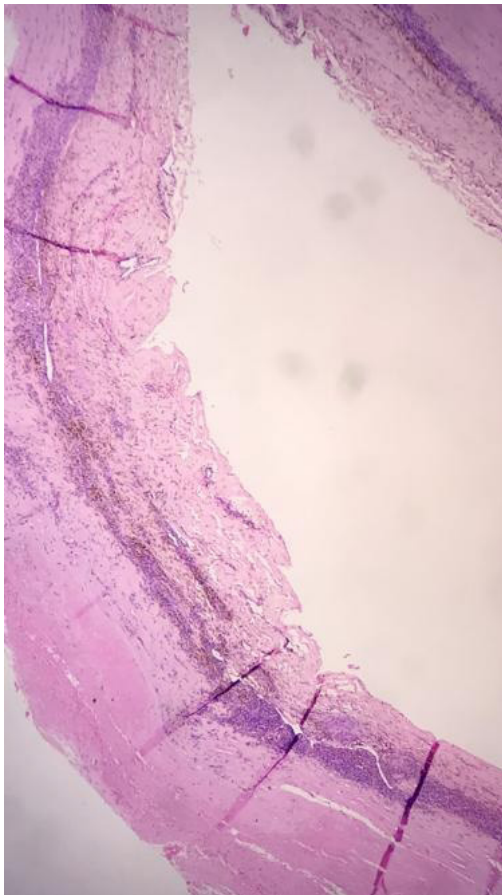
Figure 4. Result of revascularization, with interposition of Dacron® graft, proximal anastomosis with the common femoral artery (CFA), and distal anastomosis with the deep femoral artery (DFA), combined with reimplantation of the superficial femoral artery (SFA) into the graft.



**Figure 5.** Surgical specimen. Morphology of the aneurysm and its relationship to the dimensions of a number 7 scalpel handle and number 11 blade. Insert: morphology of the aneurysm after opening, showing intraluminal thrombi.



**Figure 7.** Histopathological analysis. H&E staining: x400 magnification. Acute fibrin-hematic thrombus in the process of organization.



**Figure 6.** Histopathological analysis. H&E staining: x400 magnification. Artery with dilated lumen, degenerate tunica media and adventitia with chronic inflammation.

## DISCUSSION

A systematic review of articles published in English identified 46 reports of true isolated DFA aneurysms.<sup>6</sup> Another review, from the previous year, identified a series of just over 50 cases reported.<sup>7</sup> Recently, approximately 140 cases of DFA aneurysms were described in the literature,<sup>11</sup> showing that, although the numbers are increasing, they nevertheless illustrate the rarity of this clinical entity.

Generally, aneurysms of the femoral arteries are found in combination with aneurysms of other arteries, such as the aorta and lower limb arteries, and they are bilateral in 5% of cases.<sup>1,4-8</sup> In 50% of cases, there is an association with PAD in the femoropopliteal area.<sup>4</sup> False aneurysms and pseudoaneurysms are more common in the literature, primarily posttraumatic and iatrogenic cases.<sup>6,12</sup> It is considered that the low incidence is because of containment by the adjacent muscular structures, in particular the adductor magnus muscle, surrounding and protecting the artery.<sup>3,5-8,11</sup>

The difficulty of clinical diagnosis, particularly when the aneurysm is small, is reflected in the frequency of asymptomatic cases or cases with nonspecific lower limb symptoms, such as pain, edema, and neurological symptoms.<sup>3-7,9,11</sup> The most common finding is a pulsating mass with or without pain, but these aneurysms can also be detected as incidental findings of supplementary examinations.<sup>3,6</sup> There is

also a report of differential diagnosis for incarcerated inguinal hernia, primarily in the elderly, which can have disastrous consequences if not diagnosed before the operation.<sup>2</sup>

There is a high risk of complications with DFA aneurysms, related to the difficulty in diagnosing them and the consequent longer period for which the disease remains untreated, which can result in the patient's initial presentation being thrombosis, distal embolization, and rupture.<sup>4,9</sup> Rupture is the most common complication and the risk varies from 15 to 55%, with a direct relationship between aneurysm size and risk of rupture, while DFA aneurysms generally have a larger diameter than those of the SFA.<sup>3,6,7,13</sup> The difficulties hampering reconstruction caused by distorted anatomy contribute to the high amputation rates when these aneurysms rupture.<sup>4,6</sup>

Several different surgical approaches are described in the literature,<sup>11</sup> including ligation and resection of the aneurysm in isolation<sup>6-8,11</sup> or combined with revascularization<sup>4,9</sup> using synthetic or autologous grafts, and also endovascular procedures involving implantation of covered stents<sup>1,13</sup> and embolization, although there is still a lack of data on the long-term patency of covered stents in this area.<sup>1</sup> Limitations restricting use of endovascular treatment can include extension of the disease to involve the CFA or absence of a large enough proximal landing zone to enable sealing. Ligation is considered safe, particularly when distal pulses are present and the femoral-popliteal segment is patent, but every effort should be made to achieve revascularization when the distal pulse is absent.<sup>6,7,9,11</sup> The DFA plays an important role in collateral circulation to the lower limbs in patients with PAD, which is progressive over the years.<sup>4</sup>

In order to confirm the diagnosis with certainty, CDU, CTA, and angiography are extremely useful. Multi-detector CTA or angiography is especially recommended because they will reveal other aneurysms and stenotic or occlusive arterial lesions.<sup>3,7</sup> It is also necessary to take account of the patient's anatomy and changes to it, since there are descriptions of anatomic variants in this area that could result in disaster during procedures if they are not identified in advance.<sup>14</sup>

## CONCLUSIONS

In this case, the patient had an aneurysm of the DFA and PAD and, as a result, it was necessary to perform revascularization to maintain collateral circulation and sufficient perfusion of the lower limb. The patient was offered a safe and effective surgical therapeutic option to treat the disease, without short-term postoperative complications. It should therefore be considered that

conventional surgery has an important role to play in treatment of aneurysms involving the DFA.

## REFERENCES

- Okugi S, Watanabe K, Kunii Y, Koide M. Surgical and endovascular treatment of a bilateral deep femoral artery aneurysm. *Interact Cardiovasc Thorac Surg.* 2020;30(6):945-6. <http://dx.doi.org/10.1093/icvts/ivaa031>. PMID:32170941.
- Hamasaki T, Ota R, Matsuoka Y, Kodama W, Fukino S, Nishimura K. Ruptured deep femoral artery aneurysm confused with an incarcerated inguinal hernia: a case of an elderly patient. *Int J Angiol.* 2019;28(1):28-30. <http://dx.doi.org/10.1055/s-0038-1676965>. PMID:30880889.
- Cho YP, Choi SJ, Kwon TW, et al. Deep femoral artery aneurysm presenting as lower limb swelling: a case report. *Yonsei Med J.* 2006;47(1):148-51. <http://dx.doi.org/10.3349/yjm.2006.47.1.148>. PMID:16502499.
- Maruyama Y, Ochi M, Shimizu K. Surgical management of a deep femoral artery aneurysm. *J Nippon Med Sch.* 2012;79(5):377-80. <http://dx.doi.org/10.1272/jnms.79.377>. PMID:23123396.
- Suehiro Y, Seo H, Kubota Y, Suehiro S, Hirai H. Surgical management of incidental profunda femoris artery aneurysm: a case report. *Ann Vasc Surg.* 2020;66:666.e11-4. <http://dx.doi.org/10.1016/j.avsg.2019.12.018>. PMID:31904518.
- Posner SR, Wilensky J, Dimick J, Henke PK. A true aneurysm of the profunda femoris artery: A case report and review of the english language literature. *Ann Vasc Surg.* 2004;18(6):740-6. <http://dx.doi.org/10.1007/s10016-004-0116-4>. PMID:15599634.
- Lima IA, Lima MF, Bernardes MV. Aneurisma isolado de artéria femoral profunda: relato de caso e revisão bibliográfica. *J Vasc Bras.* 2003;2(333):333-8.
- Malek AK, Tworus R, Golebiowski M, et al. Deep femoral artery aneurysm. *EJVES Extra.* 2002;3(2):39-40. <http://dx.doi.org/10.1053/ejvx.2002.0130>.
- Ikeda H, Takeo M, Murakami T, Yamamoto M. A case of deep femoral artery aneurysm. *J Surg Case Rep.* 2015;2015(8):rjv111. <http://dx.doi.org/10.1093/jscr/rjv111>. PMID:26311829.
- Eagle KA, Berger PB, Calkins H, et al. ACC/AHA guideline update for perioperative cardiovascular evaluation for noncardiac surgery. Executive summary a report of the American College of Cardiology/American Heart Association Task Force on Practice Guidelines (Committee to Update the 1996 Guidelines on Perioperative Cardiovascular Evaluation for Noncardiac Surgery). *Circulation.* 2002;105(10):1257-67. <http://dx.doi.org/10.1161/circ.105.10.1257>. PMID:11889023.
- Jang LC, Park SS. The true deep femoral artery aneurysm: a case report. *Vasc Specialist Int.* 2017;33(1):40-2. <http://dx.doi.org/10.5758/vsi.2017.33.1.40>. PMID:28377912.
- Cavalcante LP, Scarpari R, Queiróz TM, et al. Embolização de pseudoaneurisma com fistula arteriovenosa de artéria femoral profunda decorrente de ferimento por arma branca: relato de caso. *J Vasc Bras.* 2015;14(2):182-5. <http://dx.doi.org/10.1590/1677-5449.0081>.
- Lewszuk A, Madycki G. Endovascular management of a giant true aneurysm of the deep femoral artery in a patient with a history of internal diseases. *World J Surg Surg Res.* 2019;2:1-2.
- Kumar V, Kumar VV, Murlimanju BV, Naveen NS. Origem alta da artéria femoral profunda: relato de caso e revisão da literatura. *J Vasc Bras.* 2011;10(3):1-5. <http://dx.doi.org/10.1590/S1677-54492011000300010>.

---

**Correspondence**

Rodrigo Gibin Jaldin  
Universidade Estadual Paulista "Júlio de Mesquita Filho" – UNESP,  
Departamento de Cirurgia e Ortopedia, Campus de Botucatu  
Av. Prof. Mário Rubens Guimarães Montenegro, s/n  
CEP 18618-687 - Botucatu (SP), Brasil  
Tel.: +55 (14) 3880-1446  
E-mail: rodrigo.gibin@unesp.br

**Author information**

VTRSG and NDS - Residents, Cirurgia Vascular, Hospital das Clínicas, Faculdade de Medicina de Botucatu, Universidade Estadual "Júlio de Mesquita Filho" (UNESP).  
RGJ - Professor, Cirurgia Vascular, Faculdade de Medicina de Botucatu, Universidade Estadual "Júlio de Mesquita Filho" (UNESP).  
MB - PhD; Assistant professor, Cirurgia Vascular, Faculdade de Medicina de Botucatu, Universidade Estadual "Júlio de Mesquita Filho" (UNESP).  
MLS - Tenured professor, Cirurgia Vascular, Faculdade de Medicina de Botucatu, Universidade Estadual "Júlio de Mesquita Filho" (UNESP).  
RAY - Collaborating professor, Cirurgia Vascular, Faculdade de Medicina de Botucatu, Universidade Estadual "Júlio de Mesquita Filho" (UNESP).  
WBY - Full professor, Cirurgia Vascular, Faculdade de Medicina de Botucatu, Universidade Estadual "Júlio de Mesquita Filho" (UNESP).

**Author contributions**

Conception and design: VTRSG, RGJ, NDS  
Analysis and interpretation: VTRSG, RGJ, MB, MLS, RAY, WBY  
Data collection: VTRSG, RGJ, NDS  
Writing the article: VTRSG, RGJ, MB, MLS, RAY, WBY  
Critical revision of the article: VTRSG, RGJ, MB, MLS, RAY, WBY  
Final approval of the article\*: VTRSG, RGJ, NDS, MB, MLS, RAY, WBY  
Statistical analysis: VTRSG, RGJ, NDS  
Overall responsibility: VTRSG, RGJ, MB, MLS, RAY, WBY

\*All authors have read and approved of the final version of the article submitted to J Vasc Bras.