

Surgical treatment of a primary external iliac vein aneurysm

Tratamento cirúrgico de um aneurisma primário de veia ilíaca externa

Márcio Luís Lucas¹, Tiago Blaya Martins¹, Newton Aerts^{1,2}

Abstract

Primary external iliac vein aneurysms are rare and can be complicated by thrombosis, pulmonary embolism, or rupture. To date, there are only 14 cases reported in the literature. In this paper we report a case of a 25-year-old man who presented with left lower limb edema and cyanosis. Vascular ultrasonography revealed a cystic tumor in the left iliac fossa. Computed tomography angiography confirmed that the finding was an external iliac vein aneurysm, measuring 3.8 cm at its largest diameter. The patient underwent surgical treatment with resection followed by longitudinal venorrhaphy, with no complications. After the procedure left limb symptoms improved. The patient has exhibited no late complications over 44 months of follow-up.

Keywords: aneurysm; iliac vein; edema.

Resumo

Aneurismas primários da veia ilíaca são extremamente raros e podem complicar com trombose, embolia pulmonar ou ruptura. Acredita-se que existam apenas 14 casos descritos na literatura. Neste artigo, descrevemos um caso de um jovem de 25 anos, que apresentava edema e cianose do membro inferior esquerdo. A ecografia vascular revelou uma massa cística em fossa ilíaca esquerda. A angiotomografia confirmou o diagnóstico de um aneurisma da veia ilíaca externa esquerda de 3,8 cm, no maior diâmetro. O paciente foi submetido ao tratamento cirúrgico através da ressecção do aneurisma seguida de venorrafia longitudinal. Teve boa evolução pós-operatória, com um seguimento clínico de 44 meses. Houve uma melhora do edema no membro inferior esquerdo, sem complicações tardias.

Palavras-chave: aneurisma; veia ilíaca; edema.

¹Santa Casa de Misericórdia de Porto Alegre, Porto Alegre, RS, Brazil.

²Universidade Federal de Ciências da Saúde de Porto Alegre - UFCSPA, Porto Alegre, RS, Brazil.

Financial support: None.

Conflicts of interest: No conflicts of interest declared concerning the publication of this article.

Submitted: March 30, 2014. Accepted: May 05, 2015.

The study was carried out at Universidade Federal de Ciências da Saúde de Porto Alegre (UFCSPA) and at the Service of Vascular Surgery of Santa Casa de Misericórdia de Porto Alegre, Porto Alegre, RS, Brazil.

INTRODUCTION

Venous aneurysms are uncommon and primary aneurysms involving the iliac vein are extremely rare, but those that do occur may be asymptomatic or complicated by venous thrombosis, pulmonary embolism or rupture.¹⁻³ Aneurysms of the iliac vein can be primary (with no apparent definitive cause) or secondary to a proximal obstruction (for example, May-Thurner Syndrome), arteriovenous fistula, trauma or cardiovascular anomalies.² To date, there are just 14 reported cases of primary aneurysm of the iliac vein.¹⁻¹⁴ Diagnosis is difficult and treatment has not yet been standardized. In this article we describe the case of a 25-year-old man with a primary venous aneurysm involving the left external iliac vein who underwent surgical treatment with satisfactory results.

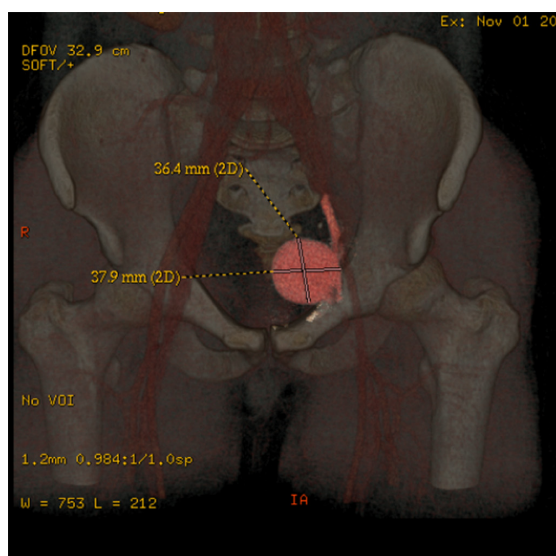


Figure 1. Reconstruction of venous angiogram showing voluminous aneurysm in left external iliac vein.

CASE REPORT

A 25-year-old, otherwise healthy male patient was admitted via emergency, presenting with spontaneous and insidious pain, swelling and a feeling of heaviness in the left lower limb. He had no history of traumas or of prior surgery. On clinical examination he exhibited edema and cyanosis of the entire left lower limb and the ipsilateral gluteal region. There were no palpable masses, murmurs or thrills anywhere in the abdominal area. Pulses in the lower limbs were symmetrical and normal. Laboratory tests found no abnormalities, but Doppler venous ultrasonography revealed a fusiform cystic mass with a maximum diameter of approximately 4.0 cm involving the left external iliac vein and with no sign of extrinsic compression. Venous angiotomography confirmed a diagnosis of a saccular venous aneurysm of the left external iliac vein with a maximum diameter of 3.8 cm and a small quantity of thrombi within the aneurysm sac (Figure 1).

The patient was given anticoagulant treatment with intravenous heparin until the time of surgery. Surgical access was obtained via a midline incision and the proximal and distal portions of the aneurysm were carefully identified and dissected, to avert the risk of embolization (Figure 2a). After systemic administration of intravenous heparin, the proximal and distal portions of the external iliac vein were clamped and longitudinal venotomy was conducted, followed by venous thrombectomy, resection of the excess vein wall and primary and continuous suture (longitudinal venorrhaphy) with Prolene 5.0 thread. After removal of the clamps, venous flow was reestablished (Figures 2c and 2c). There were no complications during surgery and no associated vascular intra-abdominal anomalies were observed. Histopathological examination of the resected venous segment did not detect any specific abnormalities. The patient recovered well with no intercurrent

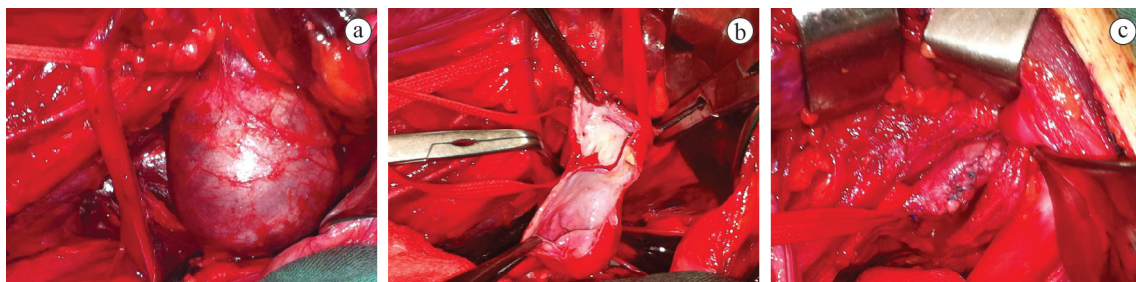


Figure 2. Sequence of intraoperative photographs. a) Aneurysm of left external iliac vein with repair to proximal and distal portions. b) Venotomy and resection of excess venous wall. c) Appearance after longitudinal venorrhaphy.

events during his stay in hospital and was discharged 5 days after surgery. At an outpatients follow-up visit, 30 days after hospital discharge, significant reduction of the edema was observed and the patients' initial complaints had completely resolved over 44 months of follow-up.

DISCUSSION

Aneurysms of the iliac vein are extremely rare. Ysa et al.² conducted a systematic review, identifying just 21 cases published in the literature, among which secondary aneurysms were most common, with ten cases related to arteriovenous fistulas caused by traumas, two patients with an associated cardiovascular anomaly, one patient with Iliac Vein Compression Syndrome, and another who developed the aneurysm after a heat injury to the iliac vein. At the time that that review was written, there were just seven published cases of primary aneurysms.² We identified 14 cases of primary venous aneurysms involving the iliac vein described in the literature, in eight of which an external iliac vein was involved¹⁻¹⁴ (Table 1). Our patient, a young man, presented with pain and edema of the left lower limb as the most important complaints. A review of cases described in the literature shows that the majority (57%) were in male patients, aged from 19 to 69 years. The other published cases (43%) were in women aged 14 to 38. The majority of patients exhibited some type of symptom related to the venous aneurysm and five patients (38%) were asymptomatic. As with our patient, the most common clinical manifestations were pain and edema (57%) in the affected limb.

These symptoms could be related to increased venous pressure, as has been reported by other authors.³ In the great majority of cases (63%) only the left iliac vein was affected, while two patients (14%) only had right iliac vein involvement and another three patients (21.5%) had bilateral involvement. Although there was a small quantity of mural thrombi, our patient's venous aneurysm was not completely thrombosed, in common with some of the cases described.^{1,4,6,7,10,11} However, in other situations, the aneurysm may be thrombosed at the time of diagnosis.^{2,3,5,8,9} Additionally, some authors have described patients with pulmonary thromboembolism secondary to an aneurysm of the iliac vein.^{4,12,14}

Since there are so few cases described, treatment of this type of aneurysm has not yet been standardized. There are a range of possibilities, depending on the patient's clinical presentation, the size of the aneurysm, extent of venous thrombosis (when present) and presence of collateral circulation. Our patient was young and exhibited significant symptoms without complete thrombosis of the venous aneurysm. We therefore chose surgical treatment, with resection of the aneurysm by partial resection of the aneurysm wall followed by longitudinal venorrhaphy. The same technique was used by other authors with satisfactory results.^{1,5,10,13} In some situations other authors have chosen complete resection of the aneurysm and reconstruction of the vein with synthetic³ or venous⁷ grafts. Fully thrombosed aneurysms causing minor clinical manifestations and/or with abundant collateral venous networks can be treated clinically using anticoagulation.^{2,9,12} In cases in which extensive

Table 1. Published cases of patients with primary aneurysms of the iliac vein.

Authors, year of publication	Sex, age (years)	Clinical presentation	Veins involved	Treatment	Follow up
Hurwitz & Gelabert ³	M, 69	Pain+edema	L common iliac	Resection+reconstruction	22 months
Postma et al. ⁴	M, 33	Pain	L internal iliac	Ligature	12 months
Petruni et al. ⁵	M, 19	Pain	L common iliac	Resection + venorrhaphy	12 months
Alatri & Radicchia ⁶	M, 39	Asymptomatic	L + R common iliac	None	n/a
Fourneau et al. ⁷	F, 21	Asymptomatic	L external iliac	Resection+reconstruction	18 months
Alonso-Perez et al. ⁸	M, 67	Edema	L+R common iliac	Ligature+anticoagulation	16 months
Banno et al. ¹	F, 20	Asymptomatic	L external iliac	Resection + venorrhaphy	16 months
Cañibano et al. ⁹	M, 69	Edema	L external iliac	Anticoagulation	1 month
Ysa et al. ²	M, 51	Fever+edema	R external iliac	Anticoagulation	3 months
Kotsis et al. ¹⁰	F, 38	Asymptomatic	L external iliac	Resection + venorrhaphy	n/a
Humphries & Dawson ¹¹	F, 32	Asymptomatic	L + R external iliac	Anticoagulation	n/a
Zou et al. ¹²	F, 14	Edema	L external iliac	Anticoagulation	n/a
Ghidirim et al. ¹³	M, 59	Pain+edema	R common iliac	Resection + venorrhaphy	36 months
Hosaka et al. ¹⁴	F, 22	Embolism	L external iliac	Resection + venoplasty	n/a
Lucas et al. ¹⁵	M, 25	Pain+edema	L external iliac	Resection + venorrhaphy	38 months

M= male; F= female; L= left; R= right; n/a= not available.

thrombosis involves the iliofemoral axis or cases in which the thrombosed segment involves the internal iliac vein, it is possible to proceed with ligation of the aneurysm only.^{4,8}

Clinical follow-up of these patients is of fundamental importance, because venous reconstructions can develop thrombosis and patients may suffer relapse of symptoms.³ Our patient has been in follow-up for 44 months with total remission of the initial complaints of edema and pain in the left lower limb, and the most recent color Doppler venous ultrasonography did not detect thrombosis. Clinical follow up periods described in the literature vary from 3 to 36 months and the majority of these patients exhibited significant improvement of symptoms; but a certain proportion of residual edema may remain, primarily in cases in which thrombosis of the venous aneurysm had occurred.²

From the perspective of pathology, the wall of the venous aneurysm may exhibit intimal fibrosis and thickening, and a reduction in the number of smooth muscle cells and thickening of the tunica media.^{1,14} Normal histopathological results have also been reported by other authors.³

In conclusion, this is a description of a rare case of primary aneurysm of the external iliac vein in which the patient exhibited symptoms of venous insufficiency in the left lower limb and was successfully treated with resection of the aneurysmal venous wall followed by longitudinal venorrhaphy, with no later complications.

REFERENCES

- Banno H, Yamanouchi D, Fujita H, et al. External iliac venous aneurysm in a pregnant woman: a case report. *J Vasc Surg.* 2004;40(1):174-8. <http://dx.doi.org/10.1016/j.jvs.2004.02.043>. PMID:15218481.
- Ysa A, Bustabad MR, Arruabarrena A, Pérez E, Gainza E, Alonso JAG. Thrombosed iliac venous aneurysm: a rare form of presentation of a congenital anomaly of the inferior vena cava. *J Vasc Surg.* 2008;48(1):218-22. <http://dx.doi.org/10.1016/j.jvs.2008.02.008>. PMID:18589237.
- Hurwitz RL, Gelabert H. Thrombosed iliac venous aneurysm: a rare cause of left lower extremity venous obstruction. *J Vasc Surg.* 1989;9(6):822-4. [http://dx.doi.org/10.1016/0741-5214\(89\)90092-X](http://dx.doi.org/10.1016/0741-5214(89)90092-X). PMID:2724468.
- Postma MP, McLellan GL, Northup HM, Smith R. Aneurysm of the internal iliac vein as a rare source of pulmonary thromboembolism. *South Med J.* 1989;82(3):390-2. <http://dx.doi.org/10.1097/00007611-198903000-00029>. PMID:2922632.
- Petrunic M, Kruzic Z, Tonkovic I, Augustin V, Fiolic Z, Protrka N. Large iliac venous aneurysm simulating a retroperitoneal soft tissue tumour. *Eur J Vasc Endovasc Surg.* 1997;13(2):221-2. [http://dx.doi.org/10.1016/S1078-5884\(97\)80024-X](http://dx.doi.org/10.1016/S1078-5884(97)80024-X). PMID:9091160.
- Alatri A, Radicchia S. [Bilateral aneurysm of the common iliac vein: a case report]. *Ann Ital Med Int.* 1997;12(2):92-3. PMID:9333318.
- Fourneau I, Reynders-Frederix V, Lacroix H, Nevelsteen A, Suy R. Aneurysm of the iliofemoral vein. *Ann Vasc Surg.* 1998;12(6):605-8. <http://dx.doi.org/10.1007/s100169900208>. PMID:9841694.
- Alonso-Pérez M, Segura RJ, Vidal ED. Thrombosed aneurysm of the infrarenal vena cava: diagnosis and treatment. *J Cardiovasc Surg.* 2002;43(4):507-10. PMID:12124563.
- Cañibano C, Acín F, Martínez E, Medina FJ, Bueno A, Lopez A. Primary iliac venous aneurysm: a case report and review of the literature. *Angiologia.* 2007;59:277-82. [http://dx.doi.org/10.1016/S0003-3170\(07\)75054-X](http://dx.doi.org/10.1016/S0003-3170(07)75054-X).
- Kotsis T, Mylonas S, Katsenis K, Arapoglou V, Dimakakos P. External iliac venous aneurysm treated with tangential aneurysmatectomy and lateral venorrhaphy: a case report and review of the literature. *Vasc Endovascular Surg.* 2008;42(6):615-9. <http://dx.doi.org/10.1177/1538574408320171>. PMID:18662910.
- Humphries MD, Dawson DL. Asymptomatic bilateral external iliac vein aneurysms in a young athlete: case report and literature review. *Vasc Endovascular Surg.* 2010;44(7):594-6. <http://dx.doi.org/10.1177/1538574410366488>. PMID:20519280.
- Zou J, Yang H, Ma H, Wang S, Zhang X. Pulmonary embolism caused by a thrombosed external iliac venous aneurysm. *Ann Vasc Surg.* 2011;25(7):982.e15-8. <http://dx.doi.org/10.1016/j.avsg.2011.03.013>. PMID:21680142.
- Ghidirim G, Mişin I, Gagauz I, Condrăţchi E. [Iliac venous aneurysm: a case report and review of literature]. *Chirurgia.* 2011;106(2):269-72. PMID:21698869.
- Hosaka A, Miyata T, Hoshina K, Okamoto H, Shigematsu K. Surgical management of a primary external iliac venous aneurysm causing pulmonary thromboembolism: report of a case. *Surg Today.* 2014;44(9):1771-3. <http://dx.doi.org/10.1007/s00595-013-0776-1>. PMID:24201597.
- Lucas ML, Martins TB, Aerts N. Tratamento cirúrgico de um aneurisma primário de veia íliaca externa. *J. Vasc. Bras. No prelo.*

Correspondence

Márcio Luís Lucas

Rua Passo da Pátria, 515/1001, Bela Vista
CEP 90460-060 - Porto Alegre (RS), Brazil
E-mail: mlucasvascular@hotmail.com

Author information

MLL - Vascular surgeon and preceptor of the Service of Vascular Surgery, Santa Casa de Misericórdia de Porto Alegre.
TBM - Former resident in Vascular Surgery, Universidade Federal de Ciências da Saúde de Porto Alegre (UFCSA), Service of Vascular Surgery, Santa Casa de Misericórdia de Porto Alegre.
NA - Adjunct professor of Vascular Surgery at Universidade Federal de Ciências da Saúde de Porto Alegre (UFCSA); Chief of the Service of Vascular Surgery, Santa Casa de Misericórdia de Porto Alegre.

Author contributions

Conception and design: MLL
Analysis and interpretation: MLL, TBM, NA
Data collection: MLL, TBM
Writing the article: MLL
Critical revision of the article: MLL, TBM, NA
Final approval of the article*: MLL, TBM, NA
Statistical analysis: N/A
Overall responsibility: MLL

*All authors have read and approved of the final version of the article submitted to *J Vasc Bras.*